

# Successful Reversal of Pulmonary Hypertension in Eisenmenger Complex

Randas J. V. Batista, José L. V. Santos, Noriaki Takeshita, Lise Eocchino, Paulo N. Lima, Marilu Goehr, Marco A. Cunha, Akira T. Kawaguchi, Tomas A. Salerno

Campina Grande do Sul, PR - Brazil

*We present a case of a 19-year old female with systemic pulmonary artery (PA) pressure due to a congenital ventricular septal defect (VSD) and atrial septal defect (ASD). She was pink at rest and cyanotic on exercise. Lung biopsy revealed grade IV pulmonary vascular changes. As a preliminary step PA was banded to increase right-to-left shunt and decrease aortic (Ao) saturation with consequent decrease in PA saturation. After one year, when she was no longer cyanotic, even on exercise, lung biopsy revealed total regression of pulmonary vascular changes. As a definitive procedure VSD and ASD were closed and PA was debanded. Cardiac catheterization one week postoperatively showed PA pressure to be 50% of systemic pressure. We postulate that reversal of pulmonary vascular changes were due to lowered PA saturation. We further believe that lower PA pressure could have contributed to this regression of pulmonary vascular changes. We performed the same procedure in six more patients with similar positive clinical response. This new concept brings renewed hope to many children who otherwise are candidates for heart lung transplantation.*

## Reversão com Sucesso da Hipertensão Pulmonar no Complexo de Eisenmenger

*Relata-se caso de uma adolescente de 19 anos, com pressão da artéria pulmonar (AP) sistêmica, devida a defeitos congênitos do septo ventricular (DSV) e atrial (DVA), que se encontrava acianótica em repouso e cianótica ao exercício. A biópsia pulmonar revelava alterações vasculares pulmonares grau IV. Como medida preliminar, a AP foi cerclada para aumentar o shunt direita-esquerda e diminuir a saturação da aorta (Ao), com consequente diminuição da saturação da AP. Um ano depois, quando não se encontrava mais cianótica, mesmo ao exercício, a biópsia pulmonar revelou total regressão das alterações vasculares pulmonares. Como procedimento definitivo, foram fechados o DSV e DAS, liberando a AP. Cateterismo cardíaco, uma semana após demonstrou ser a pressão da AP 50% da pressão sistêmica. Admitimos a possibilidade que a reversão das alterações vasculares pulmonares foi devida à baixa saturação da AP, acreditando, além disso, que a pressão da AP baixa poderia ter contribuído para essa regressão. Realizamos o mesmo procedimento em outros seis pacientes, com a mesma resposta clínica positiva. Este novo conceito trás nova expectativa a muitas crianças que, de outra maneira, seriam candidatas a transplante cardiopulmonar.*

Arq Bras Cardiol, volume 68 (nº 4), 279-280, 1997

Children with Eisenmenger complex resulting from congenital shunt lesions, such as atrial septal defect (ASD), ventricular septal defect (VSD) and patent ductus arteriosus are usually treated by heart lung transplantation. In our Country this expensive procedure is performed only in very few centers and the results are very poor<sup>1</sup>. We rec-

ommend preliminary pulmonary artery (PA) banding and second stage definitive procedure with resulting regression of pulmonary vascular changes.

## Case Report

We present a case of a 19-year-old female with severe pulmonary hypertension due to a congenital VSD, ASD with dextrocardia. She was pink at rest and cyanotic on exercise. Cardiac catheterization showed an aortic (Ao) saturation = 97%. PA-saturation = 87%. AoP = 130/80mmHg (mean=96mmHg); pulmonary artery pressure (PAP) = 125/

Hospital Angelina Caron - Campina Grande do Sul  
Correspondência: Randas J. V. Batista - Hospital Angelina Caron - Rodovia PR 506, Km 1 - 83430-000 - Campina Grande do Sul, PR - Brazil  
Recebido para publicação em 4/11/96  
Aceito em 5/3/97

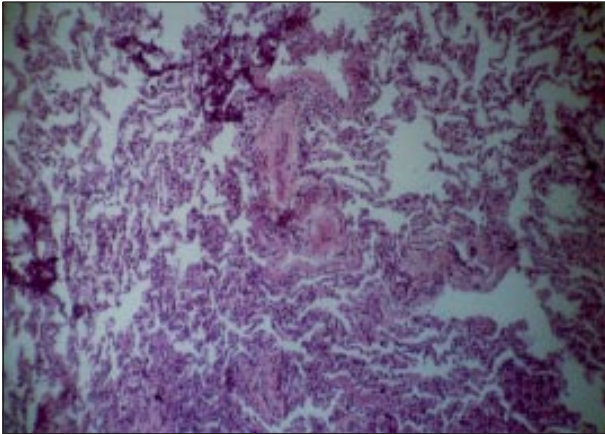


Fig. 1 - Lung biopsy showed grade IV pulmonary vascular changes.

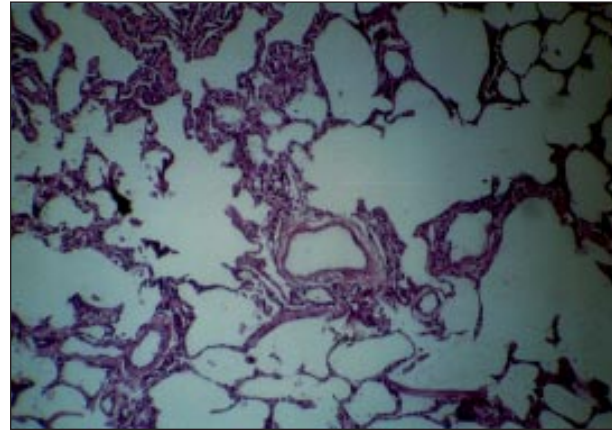


Fig. 2 - Lung biopsy showed total regression of previous lesions.

45mmHg (mean=70mmHg) unresponsive to increased inspired  $PO_2$ . Lung biopsy showed grade IV pulmonary vascular changes (fig. 1). The PA was banded to decrease aortic saturation down to 60% (room air). Thus increasing right-to-left shunt, resulting in low PA saturation (20 to 30%).

The patient left the operating room with Ao saturation of 75% and the PA saturation of 30% on room air. Systolic PA pressure was 50% of systemic. During the following year, Ao saturation increased to normal levels indicating a decrease in pulmonary vascular resistance. Cardiac catheterization at that time showed: Ao sat. = 96%, PA sat. = 88%; AoP = 127/70mmHg (mean = 90mmHg) and PAP = 68/16mmHg (mean = 41mmHg). Lung biopsy showed total regression of previous lesions (fig. 2). Subsequently PA was debanded and VSD and ASD closed. Before closing the chest, AoP was 120/80mmHg (mean = 90mmHg) and PAP was 50/20mmHg (mean = 31mmHg). At the time of discharge cardiac catheterization showed similar results.

## Discussion

It is possible that end stage congenital left-to-right

shunt lesions with fixed PA hypertension can be corrected by a two-stage procedure. We believe that the reason for the regression of lung lesions is due to lowering  $O_2$  saturation of the pulmonary artery or in combination with lower PA pressure. This lower PA saturation results in dilatation of the pulmonary vascular bed and a decrease in pulmonary vascular resistance, causing regression of fixed pulmonary lesions. We believe that high oxygen content in the PA is harmful to the arterioles, causing increased PA vascular resistance<sup>2</sup>. We also postulate that PA vascular tree has  $O_2$  sensors that mediate vascular response, contrary to the response to oxygen at alveolar level. That is: oxygen through the alveoli decreases PA vascular resistance and oxygen given through the PA increases PA vascular resistance. Then we will be able to treat also primary PA hypertension (with drugs to regulate these  $O_2$  sensors). Applying this new concept may avoid heart-lung or lung transplantation for this special indication in the future.

We have performed the first stage of this procedure in six more patients with similar positive outcome and they are waiting for the definitive procedure.

## References

1. Da Silva JP, Vila JH, Cascudo MM et al - Transplante cardiopulmonar. Experiência clínica inicial. Arq Bras Cardiol 1991; 57:103-8.
2. Cohn LH, Kosek JC, Angel WW - Pulmonary atherosclerosis produced by hyperoxic normotensive perfusion. Surgery 1971; 70: 723-9.